THE EXPERIMENT
INTERNATIONAL JOURNAL OF SCIENCE AND TECHNOLOGY

ISSN-2319-2119

RESEARCH ARTICLE
Mohamed Farouk Allam et al, The *Experiment, 2015., Vol. 33(3), 2104-2111*

TEMPOROMANDIBULAR JOINT MENISCOPEXY WITH MINI-SCREW ANCHORS

ABSTRACT

Background. Anterior disc displacement without reduction of the temporomandibular joint (TMJ) is a relatively common finding, and generally, the treatment option for these patients involves surgery, which can include multiple procedures such as arthrocentesis, eminectomy, vertical subsigmoid osteotomy, or meniscopexy. **Objective.** The purpose of this study is to clinically evaluate the effectiveness of mini-screws as anchors for meniscopexy in recurrent TMJ dislocations. **Methodology.** This was a retrospective, descriptive, non-experimental study that included 20 patients with anterior TMJ disc displacement without reduction. All patients were subjected to meniscopexy with mini-screws as anchors in combination with eminectomy. **Results.** The mean age of the participants was 26 years (ranged from 18 to 33 years), and only 3 patients were females. Postoperative hospital admission period ranged from 1 to 4 days. Mean postoperative pain scale was of 2.3 (ranged from 1 to 5). Postoperative complications were noticed in 6 (30%) patients. Ten days postoperatively, mouth opening ranged from 8 to 23 mm, and TMJ clicks were noticed in 8 (40%) patients. None of participants had recurrence of anterior TMJ disc displacement 1 year of follow up. **Conclusion.** Mini-screws as anchors for meniscopexy in patients with recurrent anterior TMJ disc displacement without reduction are safe and effective technique.

Keywords: *Temporomandibular joint, TMJ, meniscopexy, mini-screw anchors.*

INTRODUCTION

Suture anchors are an important tool in the orthopedist's armamentarium, with the main function being that of uniting soft tissues over bony structures, thus restoring function. They have mostly obviated the need for multiple drill holes when striving for secure fixation of soft tissue to bone [1-3].

Dislocation of the temporomandibular joint (TMJ) is a troublesome condition that occurs in a chronic or acute form. It is a distressing and highly embarrassing situation that may occur as a result of daily activities such as yawning, laughing, or during events that require keeping the mouth open for a long time [4]. It is one of many pathophysiologic joint conditions that the oral and maxillofacial surgeon is challenged with [4]. Different conservative and surgical techniques, like eminectomy, have been described to treat patients with a dislocated mandible [4,5].

Anterior disc displacement without reduction (ADDwoR) of the TMJ is a relatively common finding, and generally, the treatment option for these patients involves surgery, which can include multiple procedures such as arthrocentesis, eminectomy, vertical subsigmoid osteotomy, or meniscopexy [6].

The purpose of this study is to clinically evaluate the effectiveness of mini-screws as anchors for meniscopexy in treatmet of anterior TMJ disc displacement without reduction.

THE EXPERIMENT
INTERNATIONAL JOURNAL OF SCIENCE AND TECHNOLOGY

ISSN-2319-2119

RESEARCH ARTICLE
Mohamed Farouk Allam et al, The *Experiment, 2015., Vol. 33(3), 2104-2111*

METHODOLOGY

This was a retrospective, descriptive, non-experimental study that included 20 patients with anterior TMJ disc displacement without reduction. Patients were collected from the outpatient clinics of the referral military hospital in Cairo (Egypt) over three-year.

Inclusion criteria were:

1. American Society of Anesthesiology status I patients (i.e. healthy patients) with ADDwoR based on clinical examination and magnetic resonance imaging (MRI).

2. No previous surgery involving the TMJ.

3. The presence of pain, clicking of the TMJ, or limited mouth opening.

Exclusion criteria were:

1. Patients above 60 years old, because of possible arthritis which could interfere with the intervention's results.

2. Patients with trauma and fracture mandible.

3. Other pathological lesions in the TMJ.

4. Systemic rheumatic diseases like rheumatoid arthritis.

5. Psychological upset

Surgical technique

All patients underwent surgery under general anesthesia with naso-tracheal intubation, and sterile surgical preparation and draping were implemented for all patients. With digital traction of the preauricular region, a total of 5 mL of lidocaine (1% with 1:200,000 epinephrine) is infiltrated in the preauricular region at the level of the helix and the tragus with the purpose of vasoconstriction. The incision begins using a No. 15 scalpel, moving in a cephalic to caudal manner and parallel to the anatomic disposition of the auricular cartilages, separating the skin and subcutaneous tissue.

The dissection is extended 2 cm anteriorly in the subcutaneous tissue plane with a No. 15 scalpel. The first assistant separates the created flap in an anterior manner with 2 retractors. The next surgical plane is the superficial temporal fascia (confluence of the superficial musculoaponeurotic system) under which the facial nerves are located. With an Adson tissue forceps, the superficial temporal fascia is grasped5 mm anterior to the tragus and a perforation is made with a mosquito clamp and separated. The branches of the facial nerves move in an oblique and superior

ISSN-2319-2119

RESEARCH ARTICLE
Mohamed Farouk Allam et al, **The** *Experiment, 2015., Vol. 33(3), 2104-2111*

direction; for this reason, the fascia dissection (blunt dissection) is performed in an oblique and superior manner toward the zygomatic arch. The first assistant, using retractors, enters the dissected plane and retracts in an anterior and inferior manner, performing blunt dissection of the surgical plane. The second plane is elevated and dissected in the same fashion, arriving toward the temporal fascia (which appears white and shiny); at this level, the TMJ capsule is found, where a T-shaped incision is performed with an electrosurgical pencil. Dissection is performed with a Freer periosteal elevator liberating the insertion of the anterior ligament, thus enabling entrance into the superior articular space.

Disc liberation enables posterior movement and repositioning of the TMJ disc. For mini-screw anchor placement, closure of the patient mouth was done to put the condylar head in the most retruded position and grasp the most posterior part of the disc and retract it posteriorly on the condyle. We extended inferiorly with an incision that is made on the joint capsule to assess the inferior joint space; locating the condylar head and placing the mini-screw anchor on the most posterior, superior, and lateral aspects of the mandibular condyle (Figure 1). TMJ disc plication is achieved by use of two No. 2-0 nylon sutures placed on the posterior band of the disc. Thereafter we took temporo-parietal fascia and support it by 2-zero silk to the disc (Figure 2). Eminectomy was performed to facilitate joint movements. No. 4-0 Vicryl sutures are placed to reposition the surgical planes; correct repositioning and suturing of the joint capsule are of the utmost importance for appropriate wound and synovial membrane tissue healing. Finally, eminectomy was realized. The skin is then approximated and sutured with single interrupted No. 6-0 nylon sutures.

Postoperative evaluation parameters taken into account were as follows:

1. Presence of pain, quantified by use of the visual analog verbal scale, 48 hour postoperatively.

2. Presence of TMJ clicks during function, 10 days postoperatively.

3.Range of mouth opening in millimeters measured from the incisal edge of the inferior incisors to the corresponding incisal edge of the superior incisors.

Patients were followed up in the outpatient clinic every 3 months over 1 year (Figures 3 and 4).

Data analysis

Data entry screen was built using Microsoft Excel. Data was checked, coded and entered on the computer. Double data checking was done. Descriptive analysis was done: mean and standard deviation. Analysis of the data was done using SPSS (Statistical Package for Social Science version 15.0).

RESULTS

The mean age of the participants was 26 years (ranged from 18 to 33 years), and only 3 patients were females. All patients had previous recurrent anterior TMJ disc displacement without reduction and 2 patients presented with acute closed lock.

ISSN-2319-2119

RESEARCH ARTICLE
Mohamed Farouk Allam et al, The *Experiment, 2015., Vol. 33(3), 2104-2111*

Postoperative hospital admission period ranged from 1 to 4 days. Mean postoperative pain scale 48 hours after surgical intervention was of 2.3 (ranged from 1 to 5). Postoperative complications were noticed in 6 (30%) patients. Two patients had parenthesis and were managed with medical treatment and physiotherapy, with complete cure. One patient has small postoperative hematoma y and 2 patients has superficial wound infections; all cases were treated conservatively with good prognosis. Ten days postoperatively, mouth opening ranged from 19 to 43 mm, and TMJ clicks were noticed in 8 (40%) patients. None of participants had recurrence of anterior disc displacement over 1 year of follow up (Table 1).

DISCUSSION

Our descriptive study evaluated the effectiveness of mini-screws as anchors for meniscopexy in patients with recurrent anterior TMJ disc displacement without reduction. To our knowledge only 2 articles evaluated that technique [7,8].

Before reaching conclusions based on the present results, it is necessary to consider a number of potential limitations. Although our methodology can be applied in different settings, these results pertain solely to our patients attending our referral military hospital and could not be considered generalizable. Our study was conducted on 20 patients aged between 18 to 33 years old, and results in older ages could be different. However, our findings were consistent and coherent, strongly indicating the external validity of the study.

Although our patients were relatively young and aged between18 to 33 years, the average number of preoperative recurrences was 6 times. This denotes a chronic lesion, which indicated surgical intervention and meniscopexy.

Juniper (1994) reported the findings in 105 TMJ dysfunctions which have had arthrotomy for meniscopexy and menisectomy over an 8-year period. The meniscus was found to be displaced anteromedially most commonly, with the anterior position, to which reference is so frequently made, being rare; the medial position was more common [9]. In concordance with this study, all our patients with TMJ dysfunctions had anterior disc displacement without reduction.

Internal derangement of the TMJ does not always cause pain, although when the disc becomes displaced, noises and locking can occur and ligamentous, capsular or retrodiscal pain may dominate the clinical picture [10]. Our patients were selected for surgical intervention because of recurrent anterior disc displacement without reduction and acute closed lock, rather than of pain.

Recently, Ryba and collaborators described TMJ meniscopexy using the Arthrex Corkscrew® mini anchor system. The authors summarized all steps of TMJ meniscopexy using a special Corkscrew® suture anchors, specially designed for that technique [7]. The Corkscrew® family of products is part of the next generation in hand/wrist and foot/ankle repair [11]. In our study, we used standard mini-screw anchors; available in our hospitals and cheaper than Corkscrew® suture anchors.

Postoperative hospital admission period of our patients ranged from 1 to 4 days. This short period of hospital admission adds more saving for the costs of this surgical intervention.

ISSN-2319-2119

RESEARCH ARTICLE
Mohamed Farouk Allam et al, The *Experiment, 2015., Vol. 33(3), 2104-2111*

Ruiz Valero and collaborators (2011) conducted a study with 50 patients diagnosed with anterior disc displacement without reduction. All patients underwent surgical meniscopexy and placement of Mitek mini anchors with No. 2-0 nylon monofilament sutures. Postoperative analysis showed that 92% of the patients had no painful symptoms, 90% did not have any associated clicks in the TMJ, and the mean mouth opening range on postoperative evaluation was 38.3 mm [8]. Our results coincide with the results of Ruiz Valero and collaborators. In our study, mean postoperative pain scale 48 hours after surgical intervention was of 2.3, and the mean mouth opening 10 days postoperatively was 34.2 mm. Of note, TMJ clicks were more frequent in our study compared with the study of Ruiz Valero and collaborators (40% vs 10% respectively). It is also important to remember that Ruiz Valero and collaborators used special mini anchors (Mini QUICKANCHOR® Anchors) [12], more expansive than standard screws we used.

No recurrence was noted in our patients after 12 months of postoperative follow up. This proves that meniscopexy in patients with anterior TMJ disc displacement without reduction is an effective technique. Previously Sharma y collaborators (2010) reported that meniscopexy of TMJ was indicated in internal derangement of the TMJ refractory to conservative treatment with restricted movement and pain [10].

In conclusion, mini-screws as anchors for meniscopexy in patients with anterior TMJ disc displacement without reduction are safe and effective technique.

Table 1.Preoperative and postoperative results of mini-screws as anchors for meniscopexy in recurrent TMJ dislocations.

Variable	**Mean ± SD or Number (%)**
Age in years	26.05 ± 3.85
Sex (male)	17 (85%)
Number of preoperative recurrences	5.95 ± 1.57
Postoperative hospital admission period	2.55 ± 0.95
Postoperative complications	6 (30%)
Postoperative recurrence	0 (0%)

THE EXPERIMENT
INTERNATIONAL JOURNAL OF SCIENCE AND TECHNOLOGY

ISSN-2319-2119

RESEARCH ARTICLE
Mohamed Farouk Allam et al, The *Experiment, 2015., Vol. 33(3), 2104-2111*

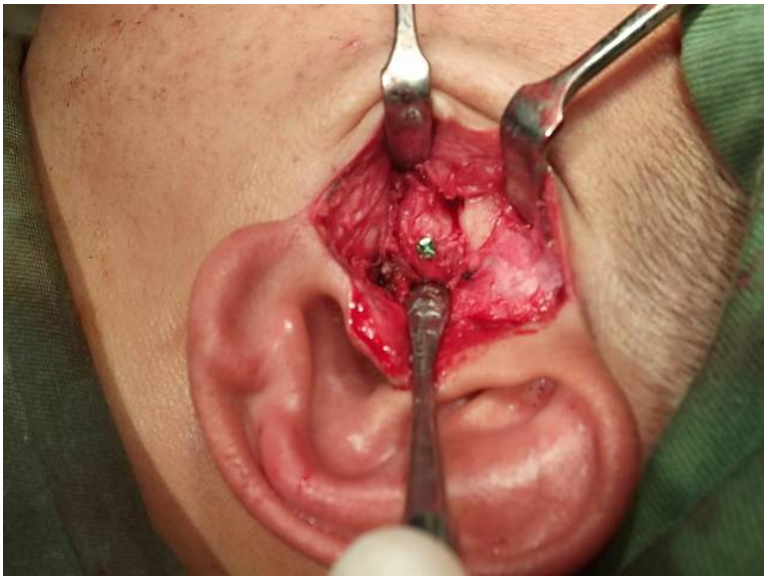

Figure (1): Mini-screw anchor placed the on the most posterior, superior, and lateral aspects of the mandibular condyle.

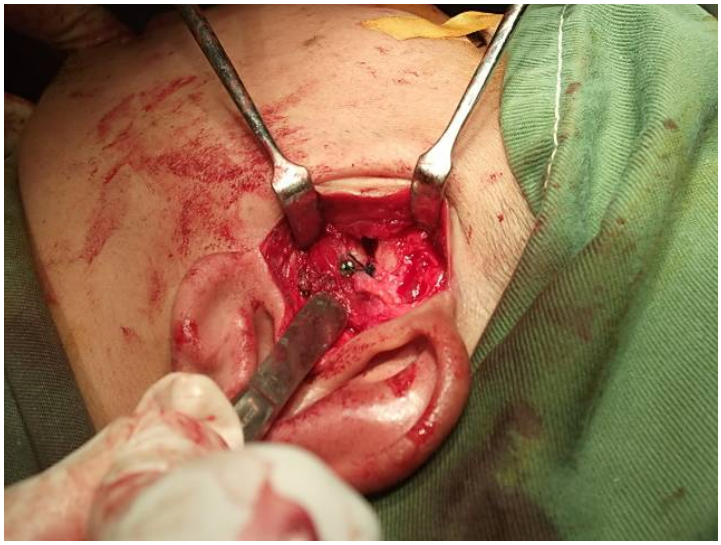

Figure (2): Temporo-parietal fascia supported to the disc by 2-zero silk.

.

THE EXPERIMENT
INTERNATIONAL JOURNAL OF SCIENCE AND TECHNOLOGY

ISSN-2319-2119

RESEARCH ARTICLE
Mohamed Farouk Allam et al, **The** *Experiment, 2015., Vol. 33(3), 2104-2111*

Figure (3): Postoperative CT.

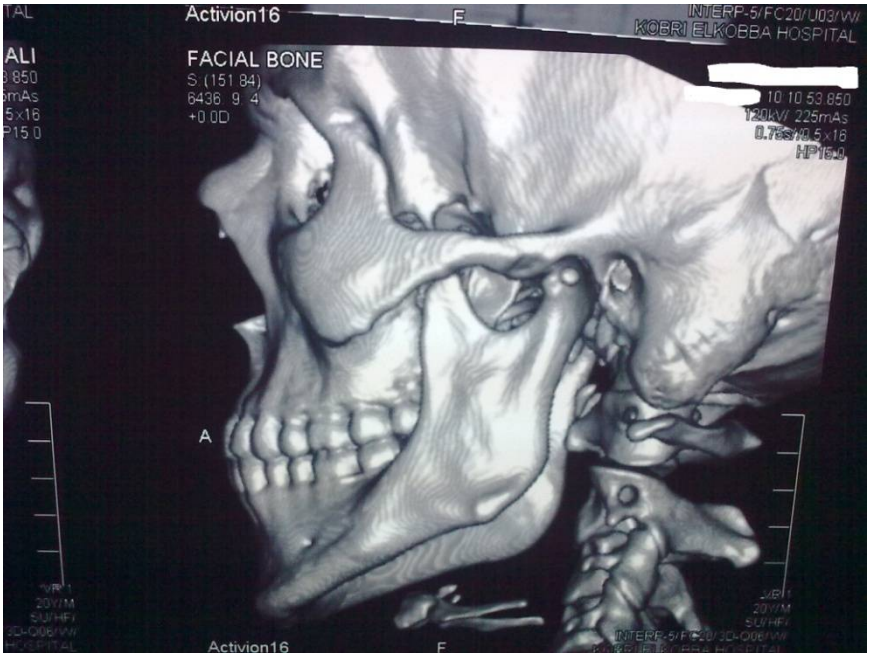

Figure (4): Postoperative CT 3D image.

ISSN-2319-2119

RESEARCH ARTICLE
Mohamed Farouk Allam et al, The *Experiment, 2015., Vol. 33(3), 2104-2111*

REFERENCES

1. Park MJ, Shin SS. Use of suture anchors and new suture materials in the upper extremity. Hand Clin 2012;28(4):511-8.
2. Dogan OF, Oznur A, Demircin M. A new technical approach for sternal closure with suture anchors (Dogan technique). Heart Surg Forum 2004;7(4):E328-32.
3. Epstein DD, Epstein PL. A clinical comparison of three overdenture anchors. Compendium 1992;13(9):762-6.
4. Martins WD, Ribas Mde O, Bisinelli J, França BH, Martins G. Recurrent dislocation of the temporomandibular joint: a literature review and two case reports treated with eminectomy. Cranio 2014;32(2):110-7.
5. Liddell A, Perez DE. Temporomandibular joint dislocation. Oral Maxillofac Surg Clin North Am 2015;27(1):125-36.
6. Oxford Handbook of Clinical Dentistry. Mitchell DA, Mitchell L and McCaul L. Sixth edition. Oxford University Press. Oxford, United Kingdom. 2014.
7. Ryba FM, Ali A, Matthews NS. Temporomandibular joint meniscopexy using the Arthrex Corkscrew® mini anchor system: technical note. Br J Oral Maxillofac Surg 2015;53(3):299-300.
8. Ruiz Valero CA, Marroquin Morales CA, Jimenez Alvarez JA, Gomez Sarmiento JE, Vallejo A. Temporomandibular joint meniscopexy with Mitek mini anchors. J Oral Maxillofac Surg 2011;69(11):2739-45.
9. Juniper RP. The shape of the condyle and position of the meniscus in temporomandibular joint dysfunction. Br J Oral Maxillofac Surg 1994;32(2):71-6.
10. Sharma R, Sinha R, Menon PS. Meniscopexy for internal derangement of temporomandibular joint. J Maxillofac Oral Surg 2010;9(3):261-5.
11. Corkscrew®. Arthrex. Available at: http://www.arthrex.com/foot-ankle/corkscrew (accessed 1 September 2015).
12. Mini QUICKANCHOR® Anchors. Mitek Sports Medicine. DePuySynthes. Available at: https://www.depuysynthes.com/hcp/mitek-sports-medicine/products/qs/Mini-QUICKANCHOR-Anchors (accessed 1 September 2015).

Author(s)

Dr. Raafat Hassan Anwar Riad, M.Sc., PhD.[1] **, Dr. Tamer Ahmed Aly Nasr,** M.Sc., PhD.[2], **Dr. Ghada Farouk Ahmed Allam,** M.Sc. PhD[3]**, Dr. Mohamed Farouk Allam*,** MPH, PhD.[4]

1.Consultant of Maxillofacial Surgery and Anesthesia, Faculty of Oral and Dental Medicine, Cairo University, Egypt.

2. Lecture of Oral and Maxillofacial Surgery, Misr International University, Egypt.

3. Consultant of Dental Laser Applications, National Institute of Laser Enhanced Sciences, Cairo University, Egypt.

4. Professor of Preventive Medicine and Public Health, Faculty of Medicine, University of Cordoba,14004, Spain.